



PATIENT

Ralphie Hankins

SPECIES

Canine

BREED

Lab Mix

SEX

Male Neutered

AGE

13 years

WEIGHT

80.3lbs

INTERPRETED BY

Maggie Machen Lamy,
DVM, DACVIM
(Cardiology)

IMAGING PERFORMED BY

Dana Alterman,
RDCS, LVT

HOSPITAL NAME

Eubank Animal Clinic

REFERRING VET

Dr. Lloyd

INVOICE

23558

DATE

4/11/22

PRESENTING CLINICAL SIGNS

History: New murmur, grade 3/6. Arrhythmia with asynchronous pulses. History of diabetes mellitus.

ELECTROCARDIOGRAPHIC FINDINGS *Note: Single lead ECGs are evaluated as a rhythm strip.

Morphology/MEA cannot be definitively commented on.

A brief single lead ECG is available; 25mm/s, 10mm/mV, 12 second duration. The underlying rhythm appears sinus in origin with an average heart rate of 90bpm (range 47-115bpm). P for every QRS complex and vice versa with dramatic rate variation. The P and QRS morphologies are positive. VPC are suspected throughout, although this should be confirmed on a six-lead tracing. Singles and couplets are appreciated with a rapid coupling interval of 250bpm. No runs of VT are appreciated.

ECG diagnosis: Suspect profound sinus arrhythmia with single and couplet VPCs.

ECHOCARDIOGRAM FINDINGS

2D, m-mode, color flow and doppler imaging is available. Mild left ventricular dilation with moderate systolic dysfunction. Mildly increased sphericity. Mild left atrial enlargement. The mitral valve appears mildly thickened with no obvious prolapse into the left atrial lumen. Mild to moderate eccentric mitral regurgitation. The tricuspid valve appears normal in form and function. No TR. Normal right heart. The aortic and pulmonic valves appear normal in morphology and mobility. No PI or AI. Normal LVOT/RVOT velocity. No pericardial or pleural effusion noted. No obvious cardiac tumors.

CARDIAC CHART

CANINE CARDIAC PARAMETERS	MR VMAX (m/s)	TR VMAX (m/s)	LA/AO (Boon method)	LA/AO (Heart Base; Swe)	FS (%)	EF (%)	EPSS (cm)
NORMAL PARAMETER	4.5-5.5	<2.7	1.3	<1.6	28-40	40-100	<0.6
PATIENT	NM	2.5	NM	1.3	21	40	NM
CANINE CARDIAC PARAMETERS	HR (BPM)	AV VMAX (m/s)	PV MAX (m/s)	BODY WEIGHT (kg)	LA 2D short axis Base view (cm)	LVIDd Avg; 2D and m-mode short axis (cm)	LVIDs Avg; 2D and m-mode short axis (cm)
NORMAL PARAMETER	50-100	0.7-1.7	0.7-1.6	BELOW	BELOW	BELOW	BELOW
PATIENT	NM	0.91	0.90	36.4	3.0	5.6	4.4
*Normal chamber parameters expressed as a mean value (SD)				3	1.27 (5.3)	2.46 (2.46)	1.36 (5.5)
BODY WEIGHT DEPENDENT PARAMETERS				5	1.40 (4.5)	2.74 (5.2)	1.60 (4.7)
*Note: All measurements based upon multi-modal images and methods. An average value is reported.				10	1.50 (3.8)	3.27 (3.5)	2.06 (3.1)
				15	1.83 (2.0)	3.71 (2.4)	2.43 (2.1)
				20	2.02 (1.9)	4.14 (2.2)	2.80 (2.0)
				25	2.18 (2.4)	4.48 (2.9)	3.10 (2.5)
				30	2.33 (3.3)	4.83 (3.9)	3.39 (3.4)
				35	2.48 (4.3)	5.17 (5.0)	3.69 (4.5)
				40	2.62 (5.2)	5.48 (6.1)	3.96 (5.4)
				50	2.88 (7.1)	6.07 (8.3)	4.46 (7.4)

Adapted from June Boon, Veterinary Echocardiography, 1998
Rishniw M and Hollis NE, J Vet Intern Med 2000; 14:429-435
Hansson et al, Vet Rad and Ultrasound 2002
Bonagura et al. Echocardiography: principles of interpretation, Vet Clin North Am 15:1177, 1995



PATIENT

Ralphie Hankins

SPECIES

Canine

BREED

Lab Mix

SEX

Male Neutered

AGE

13 years

WEIGHT

80.3lbs

INTERPRETED BY

Maggie Machen Lamy,
DVM, DACVIM
(Cardiology)

IMAGING PERFORMED BY

Dana Alterman,
RDCS, LVT

HOSPITAL NAME

Eubank Animal Clinic

REFERRING VET

Dr. Lloyd

INVOICE

23558

DATE

4/11/22

INTERPRETATION OF THE FINDINGS & FURTHER RECOMMENDATIONS

Unfortunately, this patient has changes most consistent with occult dilated cardiomyopathy (DCM). There is a decline in systolic function, accompanied by mild LV dilation. Mild to moderate MR is noted, which may suggest concurrent valve disease. The LA is only mildly increased in size, indicating relatively low risk for complication at this time. In the future the risk will likely increase for development of congestive heart failure, malignant arrhythmias (AF, VT), collapse and/or sudden death.

Systolic failure can be primary in nature (DCM) or secondary to taurine deficiency, certain drugs such as Doxorubicin, myocarditis, hypothyroidism, tachycardia-induced cardiomyopathy, or infiltrative disease such as lymphoma. In a senior large breed dog, primary disease is certainly possible. That being said, consider testing for primary causes that may be treatable such as a full thyroid panel. A cTnI level can be submitted to further investigate possible infiltrative/inflammatory damage (myocarditis; not suspected). Finally, a taurine level may be helpful (to screen for concurrent malabsorption issue). Regardless of result, I would institute a taurine supplement to cover all bases. **A thorough diet history is recommended**, assessing for grain free, boutique brands and/or exotic ingredient options with a diet change if indicated. Regardless of cause, prognosis is guarded long term with risk for complications going forward.

The ECG is also concerning, with frequent ventricular arrhythmias seen on a very brief tracing. These should be confirmed using a six-lead ECG if possible; however, concern is high. While isolated VPCs are considered relatively low risk, couplets are concerning for more sustained arrhythmias in the future. Given these findings, recommend Mexiletine as below. Sotalol is avoided due to the patient's significantly low resting heart rate. Ideally a holter monitor is recommended both before and after starting the medication, and every 6 months lifelong. Discussion with the owner is advised.

Recommend Pimobendan in this case given the totality of the findings with close monitoring to screen for progression. No additional medications are indicated at this time.

Monitor for development of a cough, labored breathing, exercise intolerance or collapse episodes in the future. Monitoring of sleeping breathing rates at home is recommended to screen for progression in the future. Mild activity restriction is advised. Omega fatty acid supplementation and mild salt restriction may be of some long-term benefit.

PLAN

Institute Pimobendan 0.25-0.3mg/kg PO q12h. A screening BP is recommended. Institute Mexiletine 5-7mg/kg PO q8h (available in 150 and 250mg capsules). Institute taurine supplement 1000mg PO q12h. Consider diet history, thyroid panel, cTnI, taurine level, etc. as discussed.

Recheck ECG or ideally a holter in 1-2 weeks to assess response.

A recheck echocardiogram is recommended in 6 months to assess for progression, sooner if clinical signs arise.



PATIENT

Ralphie Hankins

SPECIES

Canine

BREED

Lab Mix

SEX

Male Neutered

AGE

13 years

WEIGHT

80.3lbs

INTERPRETED BY

Maggie Machen Lamy,
DVM, DACVIM
(Cardiology)

IMAGING PERFORMED BY

Dana Alterman,
RDCS, LVT

HOSPITAL NAME

Eubank Animal Clinic

REFERRING VET

Dr. Lloyd

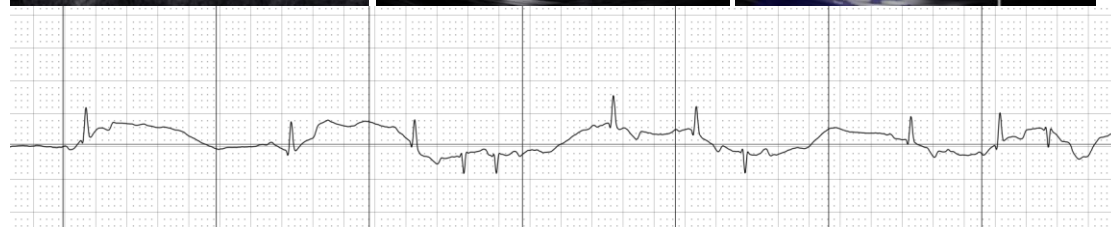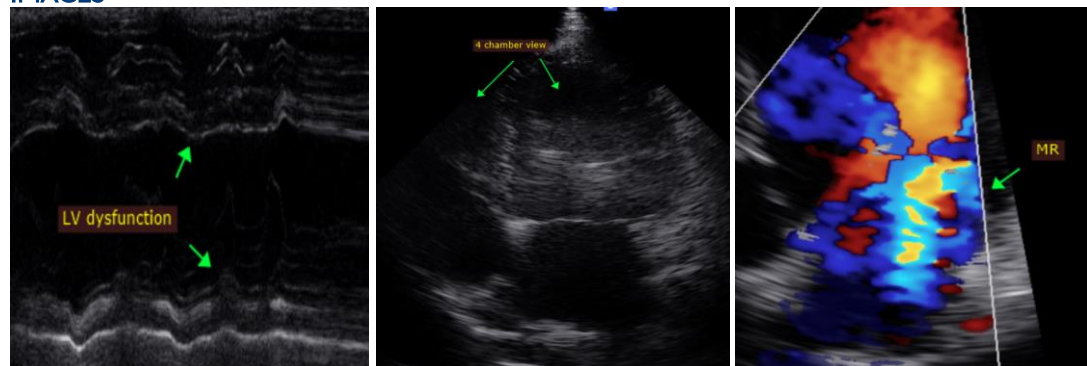
INVOICE

23558

DATE

4/11/22

IMAGES



The information and recommendations provided are based on the images presented by the referring veterinarian. No evaluation can be communicated regarding pathology that was not visible in the image/video clips provided.

Thank you for this referral. This report was generated using transcription software, and minor dictation errors may be present. If the clinical or image interpretation does not parallel your findings or if I can be of any further assistance, please contact me.

Maggie Machen Lamy, DVM
Diplomate of the American College of Veterinary Internal Medicine (Cardiology)
info@sonopath.com